

Inhibition of Sebaceous Gland Activity by Spironolactone in Syrian Hamster

CHRISTOPH LUDERSCHMIDT, M.D., FRANK BIDLINGMAIER, M.D. AND GERD PLEWIG, M.D.

Department of Dermatology and Department of Pediatrics (FB) University of Munich, Munich, Federal Republic of Germany

In the animal model of the Syrian hamster the antiandrogenic action of spironolactone on the sebaceous glands of the ventral side of the pinna was examined.

Spironolactone reduces both labeling index and cross-sectional surface area of sebaceous glands significantly in a dose-dependent manner. Equally there was a significant decrease in serum testosterone levels in spironolactone treated animals. Our results seem to justify clinical studies with spironolactone in patients with hirsutism, seborrhea, and possibly acne vulgaris.

The synthetic mineralosteroid spironolactone (SL) is routinely used as an aldosterone antagonist [1]. SL actively competes for aldosterone receptors at the distal tubule and inhibits active sodium reabsorption. It is used as a diuretic and antihypertensive medication.

A long-lasting therapy with SL is frequently associated with estrogenic side effects such as gynecomastia, impotence, and decreased libido [2,3]. These effects might be partly due to the inhibition of testosterone biosynthesis; however, the pathomechanisms of these side reactions are not yet clear [4,5]. As shown in animal experiments, the cytochrome P-450 in the microsomal testis fraction is destroyed, and consecutively, the activity of the 17- α -hydroxylase is decreased, which is necessary for the formation of testosterone from pregnenolone and progesterone [6]. Contradictory findings have been published from human volunteers, where a concomitant increase of progesterone and 17- α -hydroxyprogesterone in plasma was observed after systemic application of SL [7]; it should be noted that the SL dose used in humans was considerably lower than in the above mentioned animal experiments.

Patients, who take 200-400 mg SL daily show a more rapid metabolic clearance of testosterone [3]. Furthermore the conversion of testosterone to estradiol is increased in these individuals leading to elevated serum estradiol [3]. On this basis one could postulate changes in the common sex-hormone binding globulin (SHBG) in this manner, that increased estrogen results in an increased SHBG concentration, which limits the activity of androgens [8].

SL also has a specific antiandrogenic effect at the level of the peripheral androgen cytosol receptors and reduces the nuclear concentrations of testosterone- and dihydrotestosterone-receptor complexes, as shown in animal experiments examining the androgen receptor in the skin [9] and the prostate [10,11]. SL taken in doses such as used in the therapy of hirsute women decreases the number of available androgen binding sites [9].

The effect of SL on the sebaceous gland size and sebocyte proliferation has not been investigated. Using the animal model of the Syrian hamster ear [12-14] we investigated the effect of SL on sebaceous glands.

ANIMAL MODEL

The effects of hormones and hormonal active substances on sebaceous glands can be tested on the animal model of the Syrian hamster ear [12-14]. On the ventral sites of the pinna of the Syrian hamster there are many androgen dependent sebaceous glands. The hamster sebaceous glands form pilo-seboglular units and are comparable to human sebaceous follicles [12-14]. The size of sebaceous glands and the sebocyte proliferation of Syrian hamster reflect the activity of sebaceous glands, and therefore, the sebum production. This correlates with the serum testosterone level [14].

In hamsters testosterone shows a daily rhythm with higher values during daytime than at night and in the early morning [15]. In addition, Syrian hamsters have a marked annual cycle in reproduction activity, which is dependent from photoperiods. Long photoperiods in summer (14h daylight) lead to sexual activity with high testosterone levels. In autumn and winter, the reproductive activity is reduced, the serum testosterone concentration is diminished, and the sebaceous gland activity is minimized (unpublished data). Thus animal studies should be performed during summer months or under constant 14h light exposure imitating summer daylight periods [16].

MATERIALS AND METHODS

Animals

Experiments were done in mature long-day adapted (14h daylight) male animals (90-110 gm), kept indoors in constant temperature and maintained on a standard diet.

Treatment

Treatment was performed over a period of 24 days (6/7 days). The animals were divided into groups I and II. The animals of group I (N = 8) 0.5 mg SL (6 mg/kg BW) and the animals of group II (N = 8) 2.0 mg SL (25 mg/kg BW) were injected subcutaneously.

SL was dissolved in ricinus oil:benzyl benzoate 6:4.

Controls

These included vehicle treated (N = 5) and untreated long-day adapted male animals (N = 8).

Biopsies

All animals were biopsied 4 days after the last SL injection and at the same time between 3:00 and 4:00 PM. Specimens were fixed in formalin and wax-embedded. Sagittal sections were cut at 5 μ thickness, tangential cuts were omitted.

Testosterone Determination

Blood was collected into heparinized tubes and the plasma was separated by centrifugation and kept frozen at -20°C until assayed for testosterone. Plasma concentrations of testosterone were determined by radioimmunological methods similar to those described for estrogens [17]. In brief, plasma samples to which radioactive tracer amounts of the respective steroids have been added, were extracted with ether. The dried extracts were chromatographed on Sephadex LH-20 columns (gel bed 140 x 7 mm) with benzene/ethanol (95:5) as the solvent. The fractions were collected separately.

Final quantification of the steroids was achieved by radioimmunological methods using highly specific antisera which were raised by injecting rabbits with testosterone-3-BSA (BSA:bovine serum albumin). The sensitivity of this method was 3 ng/dl and the interassay

Manuscript received February 18, 1981; accepted for publication September 1, 1981.

Presented in part at the VIII Annual Meeting of the Arbeitsgemeinschaft Dermatologische Forschung (ADF) November 16-18, 1980, Innsbruck, Austria.

Reprint requests to: Chr. Luderschmidt, M.D., Frauenlobstr. 9-11 D-8000 München, West-Germany.

Abbreviations:

LI: Labeling index

SHBG: Sex-hormone binding globulin

SL: Synthetic mineralosteroid spironolactone

This work was supported by a grant from the Deutsche Forschungsgemeinschaft (Pl 58/6).

variability was 6.8% for testosterone. There was no interference of SL with the testosterone assay.

Measurements

Planimetric evaluation of cross-sectional surface areas were done with a standardized technique [12-14]. In short, this involved projection microscopy with a daylight projecting mirror (Zeiss), using a microscope with a $\times 25$ lens to give a final linear magnification of 420. The microscope was attached to a MOP-area counter (Kontron, Munich). 30-50 sections were made from each biopsy, more than 50 sebaceous follicles were evaluated and the results were expressed in mm^2 .

Autoradiography

Tritiated thymidine ($^3\text{H-TdR}$), specific activity 5Ci/mM (Radiochemical Centre, Amersham, England) was used to determine the labeling index (LI). Ten microcuries in normal saline were injected with a 27-gauge needle into the ventral side of each pinna. The animals were sacrificed 45 min later. The dipping method was used as described previously [18,19]. LI was determined from the ratio of labeled sebocytes to the total number of germinative sebocytes in per cent.

Statistics

For statistical analysis the independent Student's *t*-test was used.

RESULTS

Controls

There were no significant differences between the average follicle area and the LI in the vehicle treated and untreated animals (Fig 1). Microscopically, the acini were filled with sebocytes migrating from the periphery into the duct, the cytoplasm of the sebocytes increasing in size and the nucleus diminishing. The infundibula were elongated without retention of corneocytes. The results are summarized in the Table.




FIG 1. Large sebaceous glands in untreated male Syrian hamsters. Many $^3\text{H-TdR}$ labeled sebocytes (\uparrow) and keratinocytes (\uparrow). C = cartilage (reduced from $\times 220$).

Summary of experimental data using spironolactone in Syrian hamsters

Dose	Average sebaceous glands area ($\text{mm}^2 \times 10^{-3}$) and SD	Labeling index in % and SD	Serum testosterone (ng/dl) and SD
2.0 mg SL N = 8	600 \pm 335 ^a	6.5 \pm 4 ^a	48.2 \pm 21 ^a
0.5 mg SL N = 8	740 \pm 360 ^a	12.4 \pm 6 ^a	141.6 \pm 70 ^a
Controls: Vehicle treated, Untreated N = 13	1230 \pm 270 ^a	18.4 \pm 7 ^a	359 \pm 147 ^a

^a $p \leq .01$.

SD: Standard deviation.

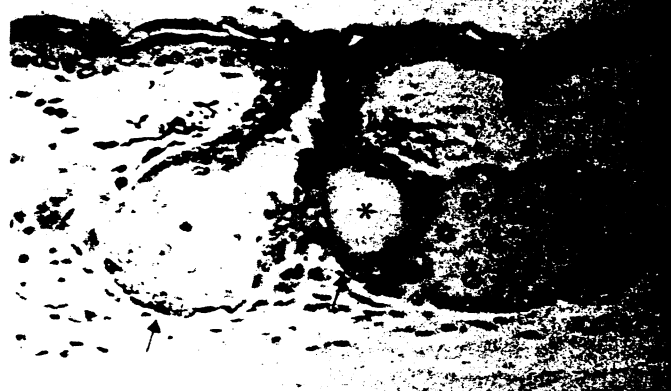

FIG 2. Reduction of sebaceous follicles with intralobular cavity (*) in Syrian hamsters treated with 0.5 mg spironolactone daily. Few labeled sebocytes (\uparrow) (reduced from $\times 220$).



FIG 3. Pronounced reduction of sebaceous follicles with cyst-like cavity (*) in Syrian hamsters treated with 2.0 mg spironolactone daily. Few labeled sebocytes (\uparrow) (reduced from $\times 220$).

Spironolactone

The SL-treated male animals differ from the controls in all parameters assessed (Table). The pelage of the animal in group I and group II became dry and lost their silky appearance compared to the pelage of the control animals. The follicle show few sebocytes and cyst-like infundibula without retention of corneocytes (Fig 2,3). The cross-sectional surface areas of sebaceous glands were reduced by 40% in group I and 53% in group II. The labeling index is decreased to 67% in group I and 35% in group II. Furthermore, the testosterone level is reduced significantly in group I by 60% and in group II by 87%.

DISCUSSION

The activity of the sebaceous glands is under control of testosterone [20,21]. The sebaceous glands are small in childhood. At the start of the puberty there is an increase of testosterone and skin surface lipids; acne vulgaris occurs if a predisposition is present. As an expression of the elevated sebaceous gland activity the sebaceous follicles are large and the $^3\text{H-TdR}$ -labeling index of the germinal cells situated on the basal membrane of the sebaceous glands is increased [18].

The mode of action of testosterone on sebocyte proliferation and lipogenesis is not yet clear. In a variety of target organs (also in the skin) testosterone is converted to dihydrotestosterone by the 5α -reductase [22-24], which is found in a high degree in sebaceous glands [25]. The intracellular action of steroid

hormones are characterized by an unitarian mode of action [26]. The cytoplasm of the androgenresponse cells is thought to be the reservoir of an androgenbinding receptor. Wide acceptance has been given that the hormone receptor complex formed in the cytoplasm migrates into the nucleus, where it exerts various influence on the properties of DNA including its transcription by RNA polymerase [27,28].

Testosterone action on sebaceous glands activity can be influenced by SL on various levels [2-7]. In the sensitive model of the Syrian hamster ear it reduces significantly the serum level of the main androgen testosterone. The elevated peripheral metabolic clearance and the increased conversion of testosterone to estradiol [3], which is sebosuppressive itself by a central inhibition of gonadotropinreleasing hormone secretion and a reduction of 5 α -reductase activity [24], might lead to a further inhibition of sebocyte proliferation. Finally, cytoplasmic androgen receptors are blocked by SL [9-11], which causes a decrease of free androgen binding sites [9]. It is not certain which of the various effects predominate but it is likely that the competitive inhibition with dihydrotestosterone for receptor sites is important.

In our animal experiments the activity of sebaceous glands was reduced significantly by SL. There was a dose-dependent decrease of the LI, that is a direct measure of sebocyte proliferation. Correspondingly, the sebocyte population was diminished, as documented by the intralobular cyst-like cavity (Fig 2,3).

Furthermore, the cross-sectional surface areas of sebaceous glands of the Syrian hamster shrank. Probably, the reduction of the follicle areas is a secondary effect caused by the inhibition of sebocytes mitoses and endogenous lipid production within the sebocytes.

Our results seem to justify clinical studies with SL in patients with hirsutism, seborrhea, and probably acne vulgaris.

The technical assistance of Miss. A. Ruhfus is kindly acknowledged.

REFERENCES

- Kagawa CM, Cella JM, Van Arman CG: Action of new steroids blocking effects of aldosterone and desoxycorticosterone on salt. *Science* 126:1015-1021, 1957
- Mann NM: Gynecomastia during therapy with spironolactone. *JAMA* 190:160-162, 1963
- Rose LI, Underwood RH, Newmark SR, Kisch ES, Williams GH: Pathophysiology of spironolactone-induced gynecomastia. *Ann Int Med* 87:398-403, 1977
- Dymling JF, Nilson KO, Hokfeld B: The effect of soldactona (conrenoate potassium) on plasma testosterone and androstenedione and urinary 17-ketosteroids and 17-hydroxycorticosteroids. *Acta Endocrinol* 70:104-112, 1972
- Steelman SL, Brooks JB, Morgan EP, Patanelli DJ: Antiandrogenic activity of spironolactone. *Steroids* 14:449-450, 1969
- Menard RH, Stripp B, Gillette JR: Spironolactone and testicular cytochrome P-450: decreased testosterone formation in several species and changes in hepatic drug metabolism. *Endocrinology* 94:1628-1636, 1974
- Stripp B, Taylor AA, Bartter FC, Gillette JR, Loriaux DL, Easley R, Menard RH: Effect of spironolactone on sex hormones in man. *J Clin Endocrin* 41:777-781, 1975
- Burke CW, Anderson DC: Sex-hormone-binding globulin is an estrogen amplifier. *Nature* 240:38-43, 1972
- Boisselle A, Dionne FT, Tremblay RR: Interaction of spironolactone with rat skin androgen receptor. *Can J Biochem* 7:1042-1046, 1979
- Corvol P, Michaud A, Menard J, Freifeld M, Mahoudeau J: Antiandrogenic effect of spironolactones: mechanism of action. *Endocrinology* 97:52-58, 1975
- Pita JC, Lippman ME, Thompson EB: Interaction of spironolactone and digitalis with 5 α -dihydrotestosterone (DHT) receptor of rat ventral prostate. *Endocrinology* 97:1521-1527, 1975
- Plewig G, Luderschmidt C: Hamster ear model for sebaceous glands. *J Invest Dermatol* 68:171-176, 1977
- Luderschmidt C, Plewig G: Effects of cyproterone acetate and carboxylic acid derivatives on the sebaceous glands of the Syrian hamster. *Arch Dermatol Res* 258:185-191, 1977
- Luderschmidt C, Plewig G: Sebaceous gland inhibition from combined prednisolon-ethinylestradiol treatment. *Arch Dermatol Res* 264:109-110, 1979
- Hoffmann K, Nieschlag E: Circadian rhythm of plasma testosterone in the male djungurian hamster (*Phodopus sungorus*). *Acta Endocrinol* 86:193-199, 1977
- Hoffmann K: Photoperiod, pineal, melatonin and reproduction in hamsters. *Progr Brain Res* 52:397-415, 1979
- Bidlingmaier F, Wagner-Barnack M, Butenandt O, Knorr D: Plasma estrogens in childhood and puberty under physiologic and pathologic conditions. *Pediatr Res* 7:901-907, 1973
- Plewig G, Christophers E: Renewal rate of human sebaceous glands. *Acta Dermatol Venereol (Stockh)* 54:177-182, 1974
- Plewig G: Acne vulgaris: proliferative cells in sebaceous glands. *Br J Dermatol* 90:623-630, 1974
- Ebling JF: Hormonal control and methods of measuring sebaceous gland activity. *J Invest Dermatol* 62:161-171, 1974
- Pochi PE, Strauss JS: Endocrinologic control of the development and activity of the human sebaceous gland. *J Invest Dermatol* 62:191-201, 1974
- Price VH: Testosterone metabolism in the skin. *Arch Dermatol* 111:1496-1502, 1975
- Gomez EC, Llewellyn A, Frost P: Metabolism of testosterone-4¹⁴C by hamster skin and flank organ. *J Invest Dermatol* 63:383-387, 1974
- Kuttann F, Mauvais-Jarvis P: Testosterone 5 α -reduction in the skin of normal subjects and of patients with abnormal sex development. *Acta Endocrinol* 79:164-179, 1975
- Takayasu S, Wakimoto H, Itami S, Sano S: Activity of testosterone 5 α -reductase in various tissue of human skin. *J Invest Dermatol* 74:187-191, 1980
- Liao S: Cellular receptors and mechanism of action of steroid hormones. *Int Rev Cytol* 41:87-94, 1975
- Kalimi M, Tsai SY, Tsai M-J, Clark JH, O'Malley BW: Effect of estrogen on gene expression in the chick oviduct. Correlation between nuclear bound estrogen receptor and chromatin initiation sites for transcription. *J Biol Chem* 251:516-523, 1976
- Thomas P, Davis P, Griffiths K: Initiation and elongation of polyribonucleotide chains on rat ventral prostate chromatin transcribed by homologous ribonucleic acid polymerase. *Biochem J* 166:189-195, 1977